

Terms, definitions and measurements to describe the sonographic features of the endometrium and intrauterine lesions: a consensus opinion from the International Endometrial Tumor Analysis (IETA) group

F. P. G. LEONE*, D. TIMMERMAN†, T. BOURNE‡, L. VALENTIN§, E. EPSTEIN¶, S. R. GOLDSTEIN**, H. MARRET††, A. K. PARSONS‡‡, B. GULL§§, O. ISTRE¶¶, W. SEPULVEDA***, E. FERRAZZI††† and T. VAN DEN BOSCH†

Departments of Obstetrics and Gynecology, *Clinical Sciences Institute L. Sacco and †††Children's Hospital, Buzzi, University of Milan, Milan, Italy, †Department of Obstetrics and Gynecology, University Hospitals KU Leuven, Leuven, Belgium, ‡Department of Obstetrics and Gynaecology, Imperial College London, London, UK, Departments of Obstetrics and Gynecology, §Malmö University Hospital and ¶Lund University Hospital, Lund University, Lund and §§University of Göteborg, Sahlgrenska University Hospital, Göteborg, Sweden, Departments of Obstetrics and Gynecology, **New York University School of Medicine, New York, NY, ‡‡University of South Florida, Tampa, FL and ¶¶Harvard Medical School, Boston, MA, USA, ††Service de Gynécologie, Centre Hospitalier Universitaire Bretonneau, Tours, France and ***Department of Obstetrics and Gynecology, San Jose Hospital, University of Santiago de Chile, Santiago, Chile

KEYWORDS: diagnosis; endometrial disease; endometrial neoplasms; endometrium; myoma; sonography; terminology; ultrasonography; uterus

ABSTRACT

The IETA (International Endometrial Tumor Analysis group) statement is a consensus statement on terms, definitions and measurements that may be used to describe the sonographic features of the endometrium and uterine cavity on gray-scale sonography, color flow imaging and sonohysterography. The relationship between the ultrasound features described and the presence or absence of pathology is not known. However, the IETA terms and definitions may form the basis for prospective studies to predict the risk of different endometrial pathologies based on their ultrasound appearance. Copyright © 2009 ISUOG. Published by John Wiley & Sons, Ltd.

INTRODUCTION

Over recent years transvaginal sonography has significantly improved our ability to accurately diagnose and manage intrauterine abnormalities. In women with postmenopausal bleeding a simple measurement of endometrial thickness can reliably discriminate between women who are at low or high risk of endometrial cancer, with an endometrial thickness of 4 mm or less decreasing the likelihood of endometrial cancer by a factor of ten both in users and non-users of hormone replacement therapy^{1–6}. In the high-risk group of women, i.e. those

with an endometrial thickness of 5 mm or more, an evaluation of endometrial morphology and vascularization using gray-scale and Doppler ultrasound imaging with or without the added use of sonohysterography (instillation of saline or gel into the uterine cavity during scanning) can be used to further refine the estimation of risk of pathology and, in particular, the risk of endometrial cancer^{7–10}. The usefulness of an ultrasound examination of the endometrium in premenopausal women with bleeding problems is much less obvious^{11,12}. Most studies reporting on ultrasonography of the uterine cavity are small, and the results are sometimes conflicting, especially those with regard to sonohysterography. It is likely that many discrepant results can be explained by differences in the definitions and terms used to describe the ultrasound findings. They may also be explained by the sample sizes being small, which means that study populations are likely to differ. Results of small studies are therefore not generalizable. The lack of standardization of terms and definitions used to describe ultrasound findings of the endometrium and the uterine cavity makes meta-analysis of small studies meaningless. Large multicenter studies are needed to clearly define the role of detailed ultrasound assessment of endometrial morphology and vascularization both before and during sonohysterography in order to discriminate between different

Correspondence to: Dr T. Van den Bosch, Department of Obstetrics and Gynecology, University Hospitals KU Leuven, Herestraat 49, 3000 Leuven, Belgium (e-mail: thierry.vandenbosch@uz.kuleuven.ac.be)

Accepted: 26 October 2009

types of endometrial pathology and other intracavitary pathology.

The International Endometrial Tumor Analysis (IETA) group was formed in Chicago at the World Congress of Ultrasound in Obstetrics and Gynecology in 2008 with the aim of agreeing on terms and definitions to describe ultrasound findings in the uterine cavity, and to develop recommendations for a standardized measurement technique for both endometrial thickness and intracavitary lesions. The terms, definitions and measurement techniques were discussed based on representative images of the uterine cavity and agreed upon by all members of the IETA group.

The IETA statement is a consensus statement on terms, definitions and measurements that may be used to describe the sonographic features of the endometrium and uterine cavity at gray-scale sonography, color flow imaging and sonohysterography. The relationship between the ultrasound features described and the presence or absence of pathology is not known. However, the IETA terms and definitions may form the basis for prospective studies to predict the risk of different endometrial pathologies based on their ultrasound appearance.

EXAMINATION TECHNIQUE

In most women the endometrium and uterine cavity should be scanned transvaginally. A transabdominal scan may be required in the presence of large fibroids or a globally enlarged uterus. When a transvaginal scan is considered inappropriate (e.g. virgo, vaginismus or secondary vaginal stenosis) or if the transabdominal scan is inconclusive, a transrectal ultrasound examination should be considered. Before the menopause, a sonographic examination should preferably be performed in the early proliferative phase (cycle day 4–6), and in postmenopausal women on cyclic hormonal replacement therapy 5–10 days after the last progestin tablet^{13,14}.

Every assessment of the uterus should start with identification of the bladder and the cervix. The position of the uterus is noted and measurements taken. The uterus is scanned in the sagittal plane from cornu to cornu and in the (oblique) transverse plane from the cervix to the fundus. Having established an overview of the whole uterus, the image is magnified to contain only the uterine corpus. The magnification should be as large as possible, focusing on the area of interest. In general the endometrium is easy to visualize. However, difficulties may arise from variations in uterine position (particularly when axial) or with uterine rotation (endometriosis or previous surgery-related adhesions). This problem may be overcome in some cases by pressing on the abdomen with the non-scanning hand, or by filling the bladder. Further problems may be encountered when the cavity is distorted by coexisting benign pathology such as adenomyosis or fibroids. Endometrial cancer may distort the endometrial–myometrial interface and should be

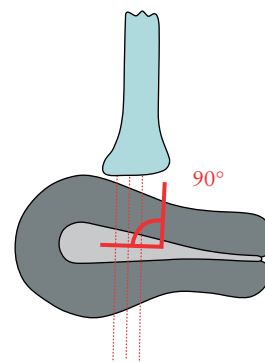


Figure 1 Schematic diagram illustrating ultrasound assessment of the endometrium; if at all possible, the angle between the endometrium and the ultrasound beam (the angle of insonation) should be 90° to optimize image quality.

considered as a possible explanation when the endometrial cavity is poorly defined.

When the endometrium is difficult to visualize, it may be helpful to trace it from the endocervical canal. If at all possible, the angle of insonation between the endometrium and the ultrasound beam should be 90° to optimize image quality (Figure 1). If the endometrium cannot be seen, saline or gel instillation often adds substantial information on endometrial appearance.

UNENHANCED ULTRASOUND EXAMINATION OF THE UTERINE CAVITY

Quantitative assessment of endometrial thickness, intrauterine lesions and intracavitary fluid

The endometrial thickness is the maximum measurement in the sagittal plane and includes both endometrial layers (double endometrial thickness). The calipers should be placed at the level of the two opposite endometrial–myometrial interfaces in an appropriately magnified image, and the endometrium should be measured where it appears to be at its thickest perpendicular to the endometrial midline (Figure 2a). The measurement of the total double-layer thickness should be reported in millimeters, rounded up to one decimal point. When intracavitary fluid is present, the thickness of both single layers are measured and the sum is recorded (Figure 2b). If the endometrium is thickened asymmetrically the largest anterior and posterior endometrial thicknesses should also be reported separately. When the endometrium cannot be seen clearly in its entirety, it should be reported as ‘non-measurable’ and no attempt made to measure it. The proportion of cases in which the endometrium cannot be measured may be as high as 10%¹⁵.

When intracavitary pathology is present the total endometrial thickness including the lesion should be recorded. However, if an intracavitary myoma is clearly identified, the myoma should not be included in the measurement of endometrial thickness. Intracavitary lesions should be measured in three perpendicular

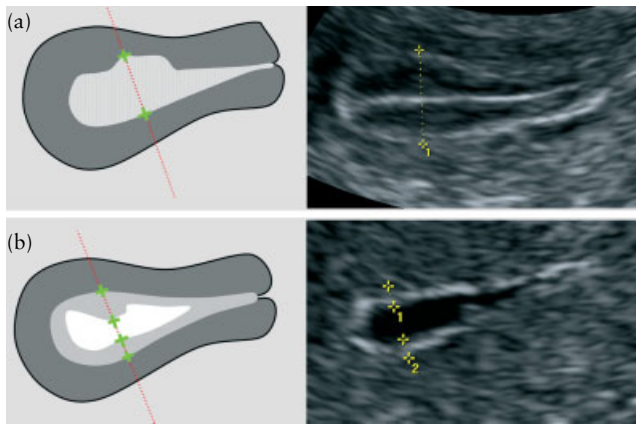


Figure 2 (a) Diagram and accompanying ultrasound image showing measurement of the endometrial thickness in the absence of intracavitary fluid; the endometrium should be measured where it appears to be at its thickest. (b) When intracavitary fluid is present, the thickness of both single layers is measured in the sagittal plane and the sum is recorded. The measurement should be taken where the endometrium appears to be at its thickest. If the endometrium is thickened asymmetrically, the anterior and posterior endometrial thicknesses should also be reported separately.

diameters in millimeters, rounded up to one decimal point. The volume of the lesion may be calculated from the three orthogonal diameters using the formula for a prolate ellipsoid ($d1 \times d2 \times d3 \times 0.523$). In myomas, the distance from the back of the myoma to the serosa should also be measured if a surgical resection is considered.

The amount of intracavitary fluid is defined by its largest measurement in the sagittal plane.

Qualitative assessment of the endometrium

An evaluation of endometrial morphology includes an assessment of endometrial echogenicity, the endometrial midline and the endometrial–myometrial junction.

The echogenicity of the endometrium is described as hyperechogenic, isoechogenic or hypoechogenic compared with the echogenicity of the myometrium. The endometrial echogenicity should be defined as ‘uniform’, if the endometrium is homogeneous and with

symmetrical anterior and posterior sides. This definition includes the different appearances seen throughout the menstrual cycle and the monolayer pattern found in most postmenopausal patients. A ‘uniform’ endometrium includes the three-layer pattern, as well as the homogeneous hyperechogenic, hypoechogenic and isoechogenic endometrium (Figure 3). The echogenicity is defined as ‘non-uniform’ if the endometrium appears heterogeneous, asymmetrical or cystic (Figure 4).

The endometrial midline is defined as ‘linear’, if a straight hyperechogenic interface within the endometrium is visualized, as ‘non-linear’ if a waved hyperechogenic interface is seen, and as ‘irregular’ or as ‘not defined’ in the absence of a distinct interface (Figure 5).

The ‘bright edge’ is the echo formed by the interface between an intracavitary lesion and the endometrium (Figure 6)¹⁶.

In some patients the endometrial interface is better detected by gently pushing the transvaginal probe against the uterine corpus, which makes the two endometrial surfaces slide against each other (i.e. the ‘sliding sign’). This technique may also be used to help characterize pathology, as small amounts of fluid in the cavity may help delineate structures in the cavity.

The endometrial–myometrial junction¹⁷ should be described as ‘regular’, ‘irregular’, ‘interrupted’ or ‘not defined’ (Figure 7).

Synechiae are defined as strands of tissue crossing the endometrium (Figure 8). Congenital anomalies are not covered in this document.

Intracavitary fluid is described as ‘anechogenic or of low-level echogenicity’, ‘ground glass’ or of ‘mixed’ echogenicity (Figure 9).

Color and power Doppler assessment

The color and power Doppler box should include the endometrium with the surrounding myometrium. Magnification and settings should be adjusted to ensure maximal sensitivity for blood flow (ultrasound frequency at least 5.0 MHz, pulse repetition frequency 0.3–0.9 kHz,

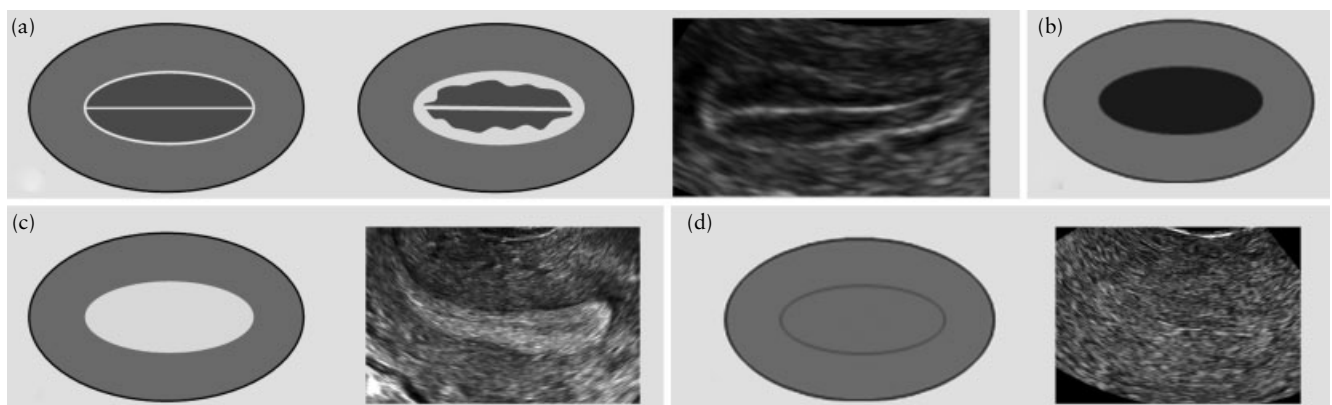


Figure 3 ‘Uniform’ endometrial echogenicity: three-layer pattern (a), hypoechogenic (b), hyperechogenic (c) and isoechogenic (d).

wall filter 30–50 Hz, color power Doppler gain should be reduced until all color artifacts disappear).

The color content in the endometrium may be scored using the International Ovarian Tumor Analysis (IOTA) color score applied previously to ovarian masses¹⁸. The

color score is a subjective semiquantitative assessment of the amount of blood flow present: a color score of 1 is given when no color flow signals reflecting blood flow can be found in the endometrium, a score of 2 when only minimal color can be detected, a score of 3 when moderate color is present, and a score of 4 when abundant color is detected (Figure 10).

The vascular pattern within the endometrium is reported with respect to the presence or absence of ‘dominant vessels’ or of other specific patterns. ‘Dominant vessels’ are defined as one or more distinct vessels (arterial and/or venous) passing the endomyometrial junction (Figure 11). The dominant vessel may show branching within the endometrium, which may be described as either orderly or disorderly/chaotic. Dominant vessels may present as a single vessel (formerly referred to as the ‘pedicle artery sign’)¹⁹ with or without branching. Multiple dominant vessels may have a ‘focal origin’ at the endometrial–myometrial junction or may have a ‘multifocal origin’. Other vascular patterns within the endometrium include scattered vessels (dispersed color signals within the endometrium but without visible origin at the myometrial–endometrial junction) and circular flow (Figure 11).

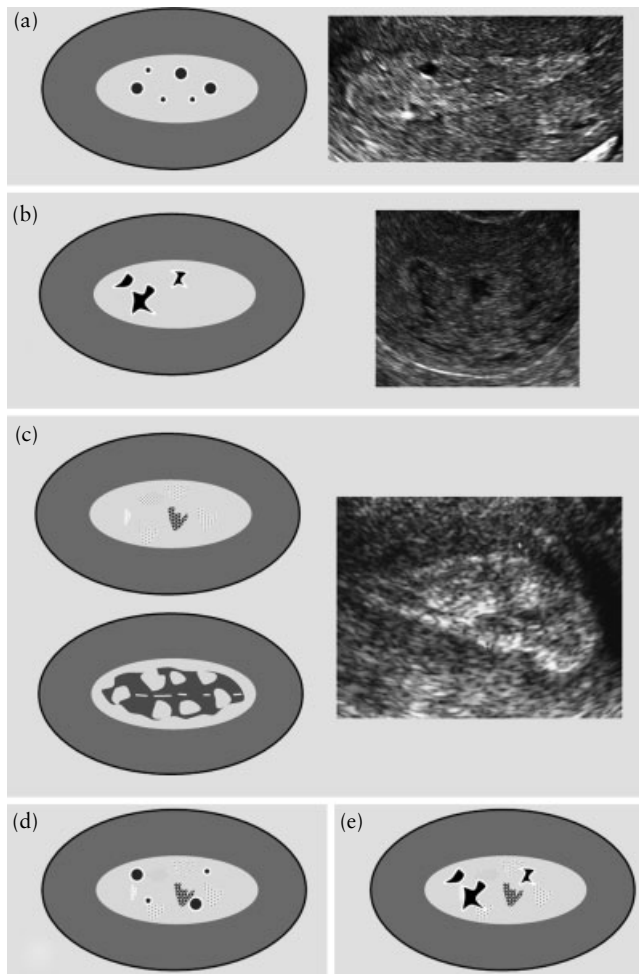


Figure 4 ‘Non-uniform’ endometrial echogenicity: homogeneous background with regular cystic areas (a), homogeneous background with irregular cystic areas (b), heterogeneous background without cystic areas (c), heterogeneous background with regular cystic areas (d) and heterogeneous background with irregular cystic areas (e); black color denotes cystic spaces.

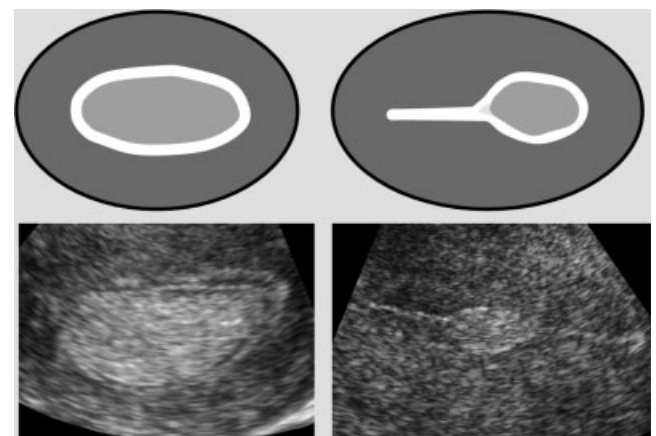


Figure 6 ‘Bright edge’, the echo formed by the interface between an intracavitary lesion and the endometrium.

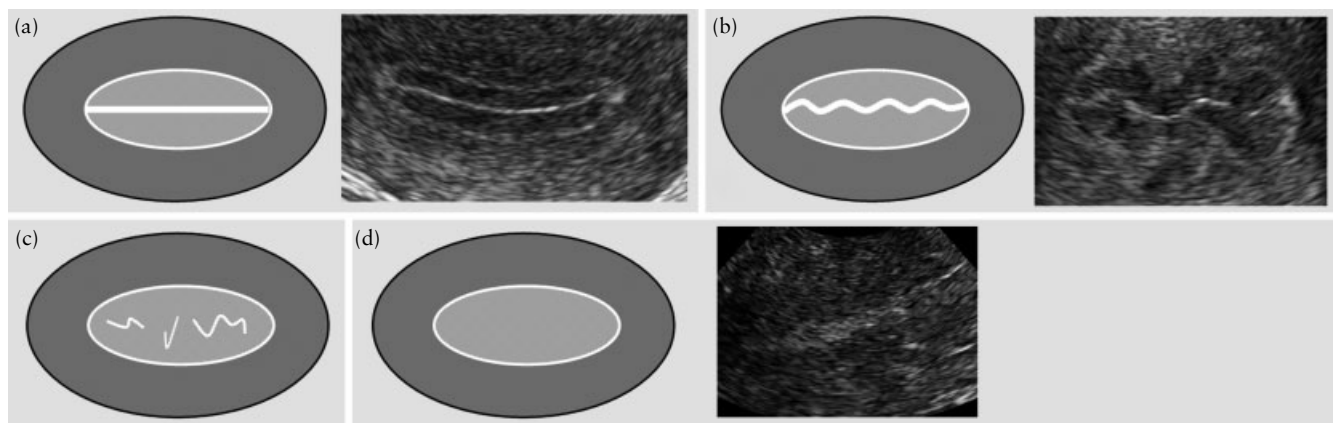


Figure 5 Endometrial midline: ‘linear’ (a), ‘non-linear’ (b), ‘irregular’ (c) and ‘not defined’ (d).

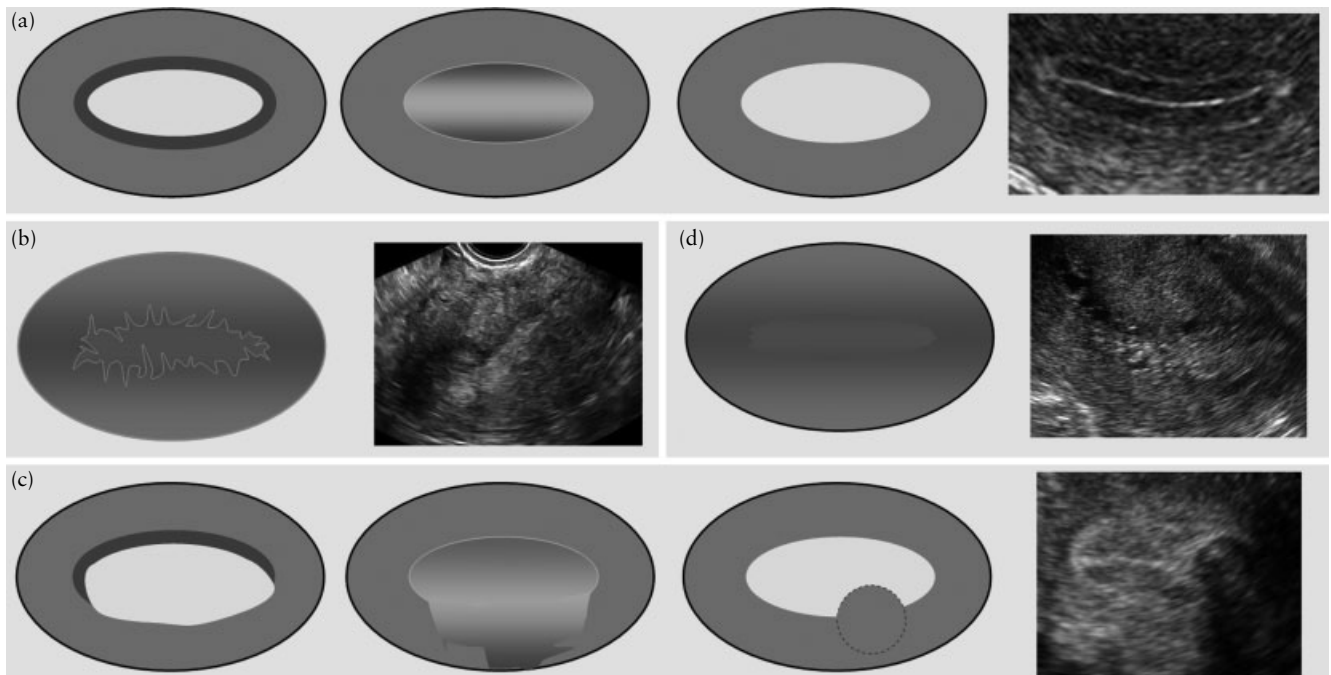


Figure 7 Endometrial–myometrial junction: ‘regular’ (a), ‘irregular’ (b), ‘interrupted’ (c) (dark gray area denotes the endometrial–myometrial halo; in this case the halo is interrupted) and ‘not defined’ (d).

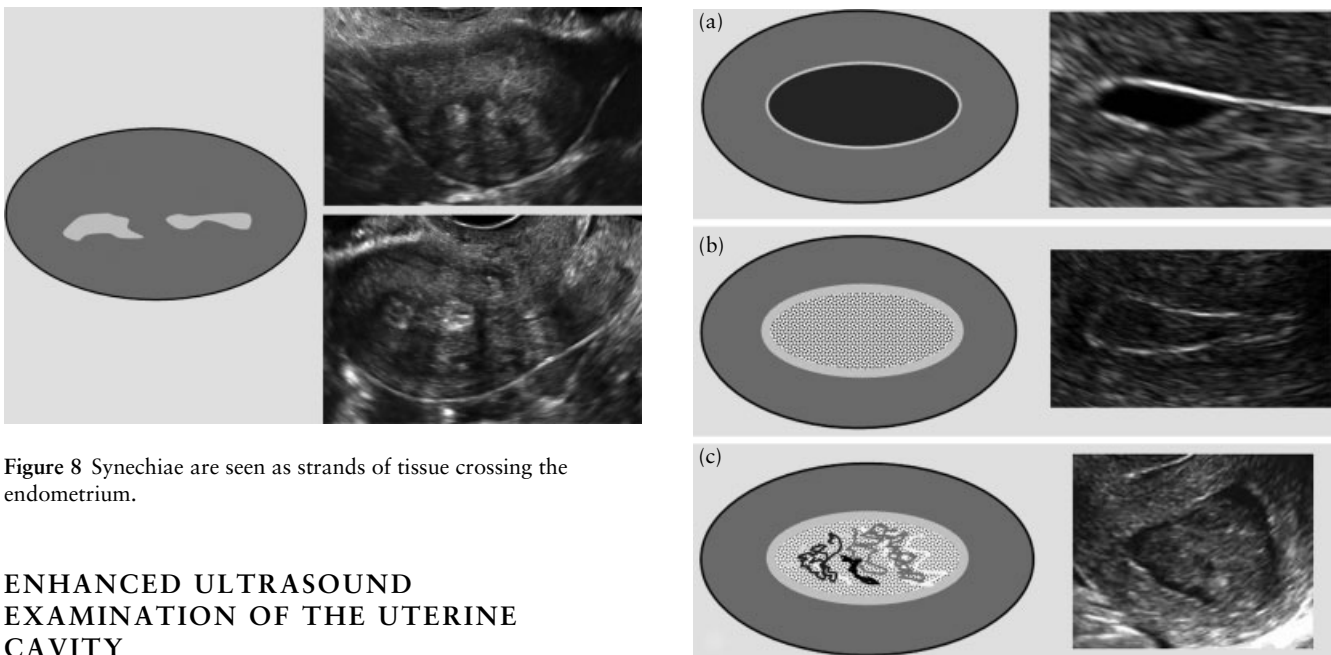


Figure 8 Synechiae are seen as strands of tissue crossing the endometrium.

ENHANCED ULTRASOUND EXAMINATION OF THE UTERINE CAVITY

Qualitative assessment of endometrial morphology and intrauterine lesions at sonohysterography or when there is pre-existing fluid in the uterine cavity

Sonohysterography is the instillation of fluid into the uterine cavity to act as a negative contrast agent. Saline instillation sonohysterography or gel instillation sonohysterography may be used^{20–23}. Evaluation of the endometrial and intracavitary morphological features at sonohysterography is done using the same definitions as described above.

Uterine cavity distension at sonohysterography is defined as ‘optimal’ if the fluid clearly distends the cavity,

Figure 9 Intracavitary fluid: ‘anechoic’ or ‘low-level’ echogenicity (a), ‘ground glass’ appearance (b) and ‘mixed’ echogenicity (c).

‘suboptimal’ if the cavity is barely distended and ‘failed’ if no fluid is seen in the cavity.

The endometrial thickness is measured as described above, and its echogenicity is described as outlined above.

The endometrial outline is defined as smooth if the endometrial surface facing the uterine cavity appears regular, as having endometrial folds (multiple thickened ‘undulating’ areas, ‘moguls’ with a regular profile), or as ‘polypoid’ if there are deep indentations. The

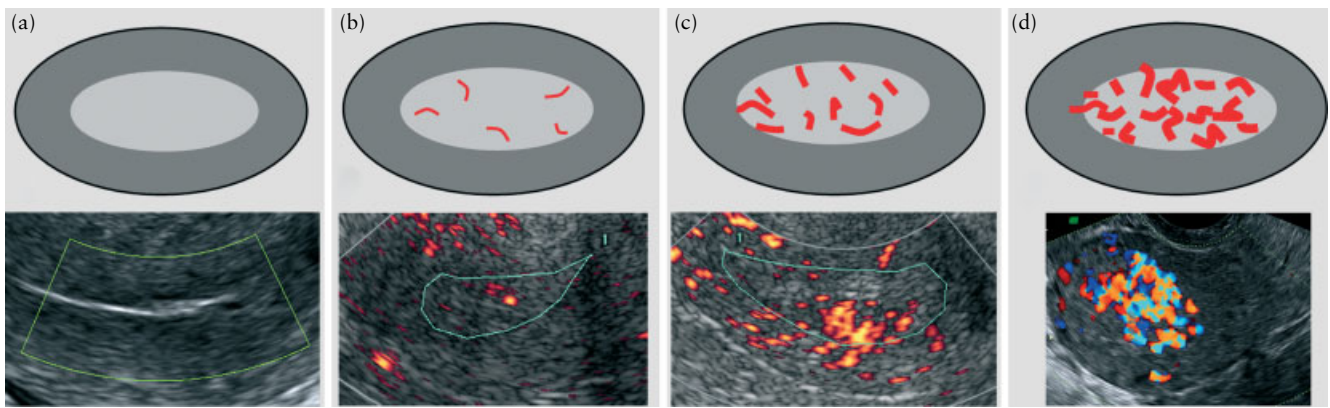


Figure 10 Color Doppler assessment of the endometrium: a color score of 1 is given to indicate no color, i.e. no flow (a); a score of 2 indicates minimal color, i.e. minimal flow (b); a score of 3 indicates moderate color, i.e. moderate flow (c); and a score of 4 indicates abundant color, i.e. abundant flow (d).

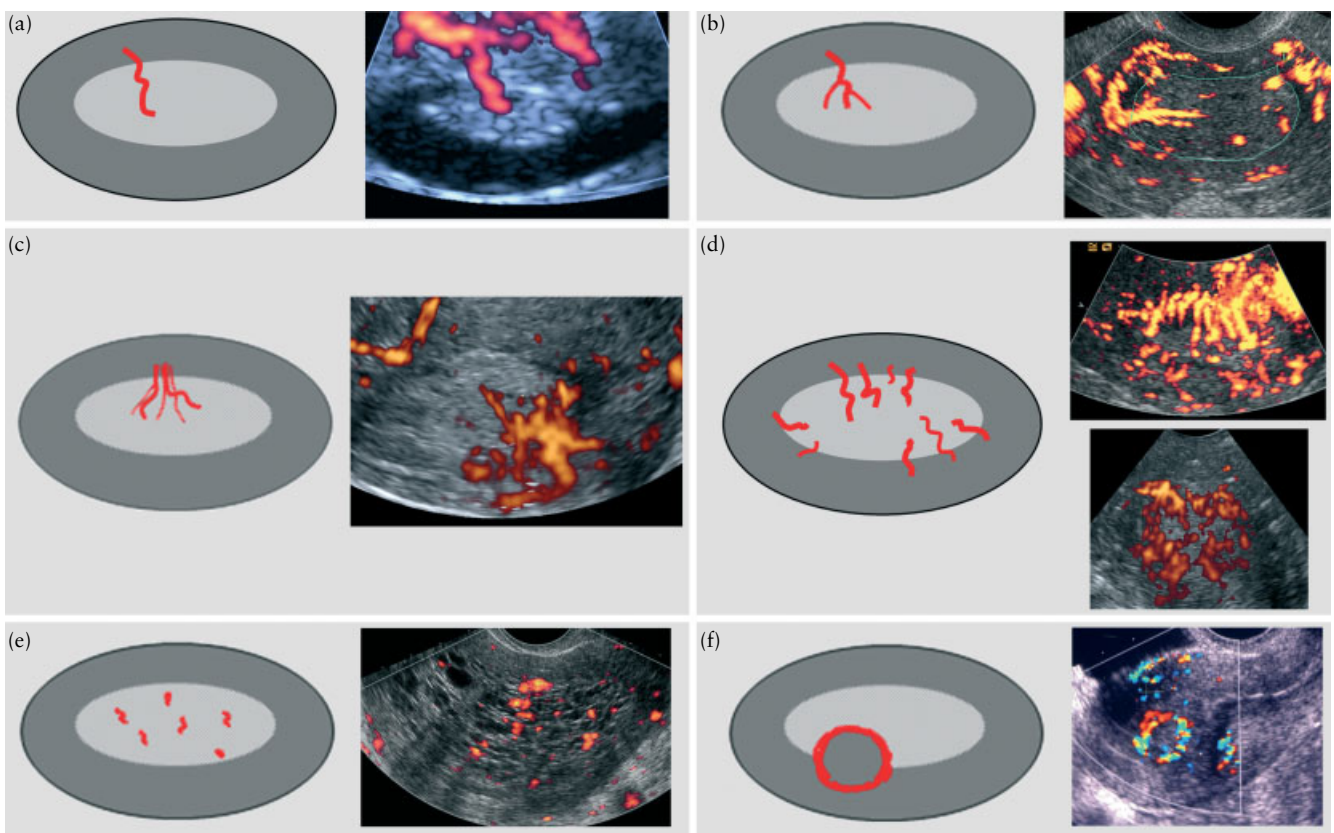


Figure 11 Vascular patterns: single 'dominant' vessel without branching (a) and with branching (b), multiple vessels with 'focal origin' (two or more vessels appear to share a common stem) (c) and with 'multifocal origin' at the myometrial–endometrial junction (d), 'scattered' vessels (dispersed color signals within the endometrium but without visible origin at the myometrial–endometrial junction) (e) and circular flow (f).

endometrium is described as 'irregular' if the surface facing the uterine cavity is cauliflower like or sharply toothed ('spiky') (Figure 12).

The endometrial–myometrial junction is described as outlined above.

Intracavitary lesions

Anything that protrudes into a fluid-filled uterine cavity is called an intracavitary lesion. Intracavitary lesions should

be described as endometrial lesions or as lesions arising from the myometrium.

The extent of an endometrial lesion is reported on the basis of the percentage of the total endometrial surface involved. The percentage is estimated subjectively by the sonographer. An endometrial lesion is defined as 'extended' if the endometrial abnormality seems to involve 25% or more of the endometrial surface, and as 'localized' if the endometrial abnormality seems to involve less than 25% of the endometrial surface (Figure 13). The

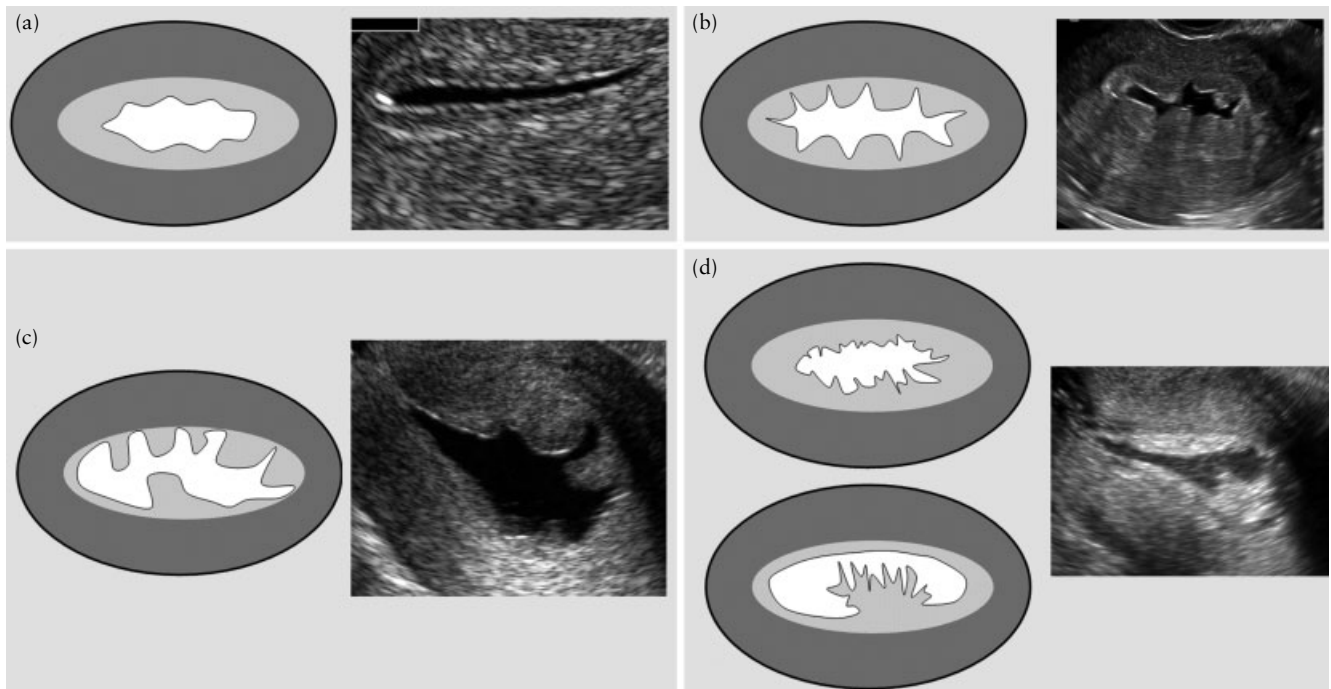


Figure 12 Endometrial outline at sonohysterography or when there is pre-existing fluid in the uterine cavity: ‘smooth’ (a), ‘endometrial folds’ (b), ‘polypoid’ (c) and ‘irregular’ (d).

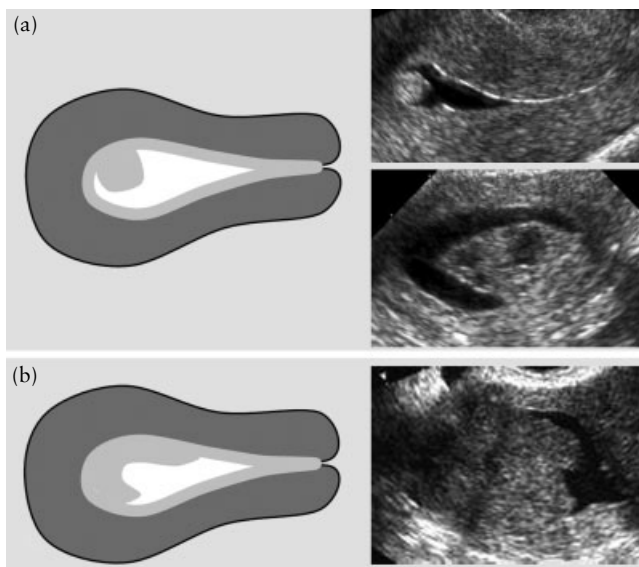


Figure 13 Estimation of the extent of an endometrial lesion at sonohysterography or when there is pre-existing fluid in the uterine cavity: ‘localized’ – the base of the lesion involves less than 25% of the endometrial surface (a) or ‘extended’ – the base of the lesion involves 25% or more of the endometrial surface (b).

type of ‘localized’ lesion depends on the ratio between the diameter of the base at the level of the endometrium (a) and the maximal transverse diameter of the lesion (b). It is defined as ‘pedunculated’ if the a/b ratio is < 1 , and ‘sessile’ if it is 1 or more (Figure 14).

The echogenicity of a lesion is defined as ‘uniform’ or ‘non-uniform’; the latter includes cystic lesions (see above under unenhanced ultrasound examination).

The outline of the lesion is defined as ‘regular’ or ‘irregular’ (e.g. spiky or cauliflower like) (Figure 15).

The presence of intracavitary lesions arising from the myometrium (usually fibroids) is defined by the echogenicity and the proportion of the lesion that projects into the uterine cavity (grading).

The echogenicity of intracavitary lesions arising from the myometrium may be uniform or non-uniform.

Submucous fibroid grading should be performed by considering specific planes passing through the largest diameter of the myoma as described by Leone *et al.*^{24,25}: Grade 0 (G0), fibroid completely within the cavity, pedunculated and without intramural extension; Grade 1 (G1), sessile fibroid, with $\geq 50\%$ of the endocavitary portion protruding into the cavity; and Grade 2 (G2), with the endocavitary part of the fibroid $< 50\%$ (Figure 16).

Synechiae are thin or thick strands of tissue crossing the endometrial cavity, usually with an echogenicity similar to that of the myometrium; they are attached to both uterine walls and are not covered by endometrium (Figure 17). The uterine cavity is often not fully distensible at sonohysterography in the presence of synechiae.

Color score (subjective assessment from 1 to 4) and the presence of ‘dominant vessel(s)’ or other vascular patterns within the lesion are described as outlined above under the heading unenhanced ultrasound examination.

DISCUSSION

In this paper we have tried to define the terms and definitions that may be used to measure and describe pathology affecting the endometrial cavity. This represents the opinion of a group of gynecologists with an interest in ultrasonography and hysteroscopy, and so should be reasonably representative. Not all clinicians will

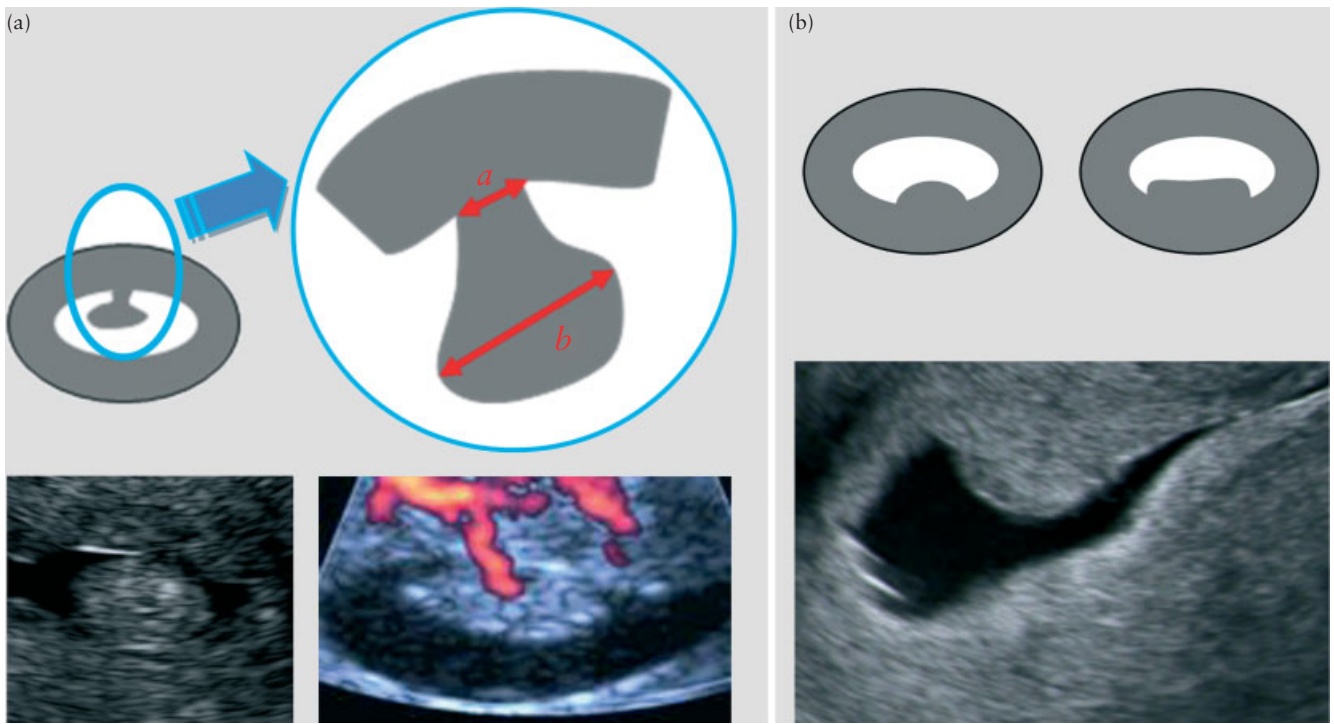


Figure 14 Type of ‘localized’ lesion at sonohysterography or when there is pre-existing fluid in the uterine cavity: a/b ratio < 1 indicates ‘pedunculated’ (a) and a/b ratio ≥ 1 indicates ‘sessile’ (b), where a is the maximal diameter of the base of the lesion at the level of the endometrium and b is the maximal transverse diameter of the lesion.

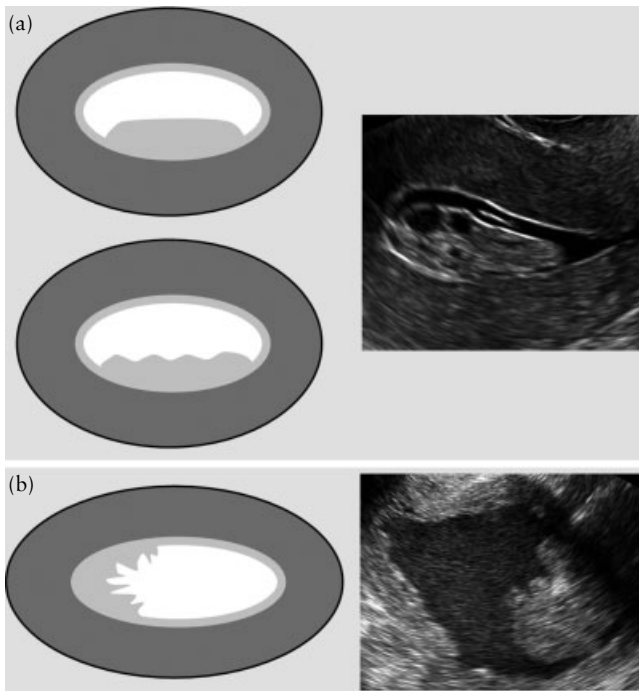


Figure 15 Outline of a lesion at sonohysterography or when there is pre-existing fluid in the uterine cavity: ‘smooth’ (a) and ‘irregular’ (b).

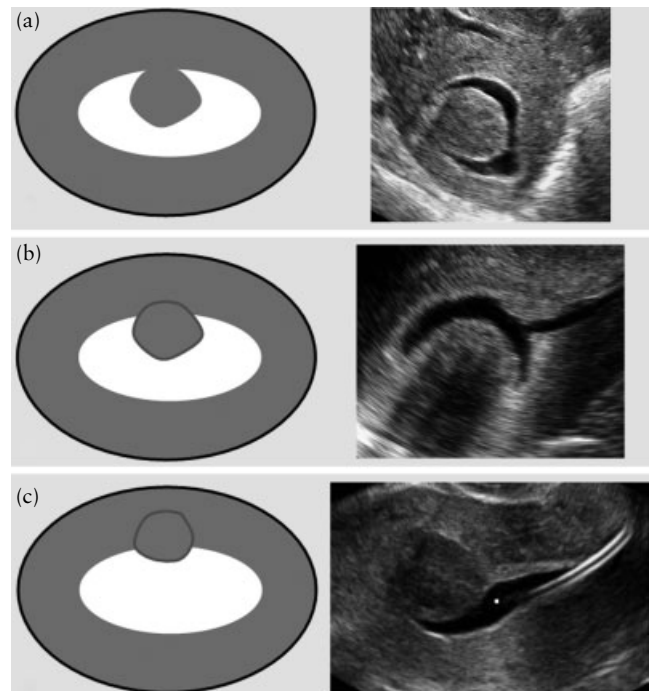


Figure 16 Proportion of a myoma protruding into the uterine cavity at sonohysterography or when there is pre-existing fluid in the uterine cavity: 100%, Grade 0 (a); $\geq 50\%$, Grade 1 (b); $< 50\%$, Grade 2 (c).

choose to use this approach to reporting their ultrasound findings. However, the primary aim of this paper is to produce a list of terms and definitions that may be used in research. Currently it is difficult to compare results from different published studies because authors use different

terms when describing the same structures or presumed pathology. The IOTA study has shown that terms and definitions can be agreed on to describe gynecological ultrasound findings¹⁸. The IOTA terms and definitions

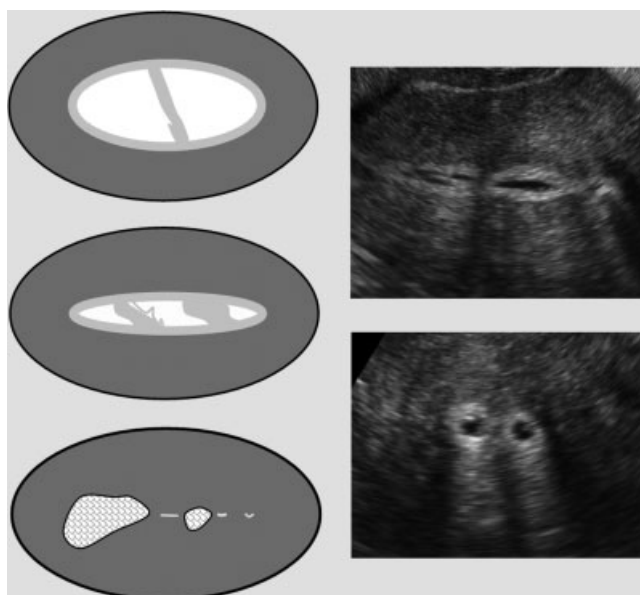


Figure 17 Synechiae at sonohysterography or when there is pre-existing fluid in the uterine cavity are thin or thick strands of tissue crossing the endometrial cavity, usually with an echogenicity similar to that of the myometrium; they are attached to both uterine walls and are not covered by endometrium.

have been used in large multicenter studies and the results have been validated successfully²⁶; hopefully, the morphological and blood flow descriptors used in the IOTA study will gradually be adopted as the standard language to describe ovarian pathology. We hope that a similar approach to the endometrium will also prove successful.

Standardizing terminology will allow comparisons between future studies on the endometrium and facilitate multicenter studies. At present we do not know which of the features outlined in the document are relevant in terms of the prediction of pathology. Endometrial thickness is certainly important as a predictor of pathology, but endometrial morphology may prove just as useful once we can be certain that investigators are looking at the same structures and evaluating the same morphological features. In particular, it might be useful in premenopausal patients, in whom endometrial thickness has been shown to be of limited value as a predictor of abnormal findings^{11,12}. Future studies will determine which features are relevant for the prediction of intrauterine pathology in both premenopausal and postmenopausal women. Other techniques, such as three-dimensional ultrasound imaging^{27–29} and the evaluation of endometrial peristalsis³⁰, might also prove useful in the diagnosis of endometrial pathology, but in this document we have limited ourselves to two-dimensional gray-scale ultrasound and color flow imaging.

In daily practice, an ultrasound report on the endometrium may be less detailed than described in Appendix S1 (IETA data sheet). However, further prospective studies will have to demonstrate which are the most important items in reporting on the endometrium

and on intracavitary lesions, before providing guidelines as to the required essential information.

Not everyone will agree with the terms and definitions that we suggest. However, to allow consistent reporting of research results, it is necessary to propose some kind of structure to describe gynecological ultrasound findings. We feel we have developed a nomenclature that is reasonable. Clinicians in the IETA group from several countries and with an interest in both ultrasound imaging and operative hysteroscopy have agreed on this nomenclature. Prospective studies will show if it needs to be adjusted.

REFERENCES

1. Smith-Bindman R, Kerlikowske K, Feldstein VA, Subak L, Scheidler J, Segal M, Brand R, Gracy D. Endovaginal ultrasound to exclude endometrial cancer and other endometrial abnormalities. *JAMA* 1998; **280**: 1510–1517.
2. ACOG Committee. ACOG Committee Opinion No. 426: the role of transvaginal ultrasonography in the evaluation of postmenopausal bleeding. *Obstet Gynecol* 2009; **113**: 462–464.
3. Ferrazzi E, Torri V, Trio D, Zannoni E, Filiberto S, Dordoni D. Sonographic endometrial thickness: a useful test to predict atrophy in patients with postmenopausal bleeding. An Italian multicenter study. *Ultrasound Obstet Gynecol* 1996; **7**: 315–321.
4. Van den Bosch T, Van Schoubroeck D, Domali E, Vergote I, Moerman P, Amant F, Timmerman D. A thin and regular endometrium on ultrasound is very unlikely in patients with endometrial malignancy. *Ultrasound Obstet Gynecol* 2007; **29**: 674–679.
5. Gull B, Karlsson B, Milsom I, Granberg S. Can ultrasound replace dilation and curettage? A longitudinal evaluation of postmenopausal bleeding and transvaginal sonographic measurement of the endometrium as predictors of endometrial cancer. *Am J Obstet Gynecol* 2003; **188**: 401–408.
6. Karlsson B, Granberg S, Wikland M, Ylostalo P, Torvid K, Marsal K, Valentin L. Transvaginal ultrasonography of the endometrium in women with postmenopausal bleeding – a Nordic multicenter study. *Am J Obstet Gynecol* 1995; **172**: 1488–1494.
7. Epstein E, Skoog L, Isberg PE, De Smet F, De Moor B, Olofsson PA, Gudmundsson S, Valentin L. An algorithm including results of gray-scale and power Doppler ultrasound examination to predict endometrial malignancy in women with postmenopausal bleeding. *Ultrasound Obstet Gynecol* 2002; **20**: 370–376.
8. Epstein E, Valentin L. Gray-scale ultrasound morphology in the presence or absence of intrauterine fluid and vascularity as assessed by color Doppler for discrimination between benign and malignant endometrium in women with postmenopausal bleeding. *Ultrasound Obstet Gynecol* 2006; **28**: 89–95.
9. Opolskiene G, Sladkevicius P, Valentin L. Ultrasound assessment of endometrial morphology and vascularity to predict endometrial malignancy in women with postmenopausal bleeding and sonographic endometrial thickness \geq 4.5 mm. *Ultrasound Obstet Gynecol* 2007; **30**: 332–340.
10. Opolskiene G, Sladkevicius P, Valentin L. Two- and three-dimensional saline contrast sonohysterography: interobserver agreement, agreement with hysteroscopy and diagnosis of endometrial malignancy. *Ultrasound Obstet Gynecol* 2009; **33**: 574–582.
11. Dijkhuizen FP, Brölmán HA, Potters AE, Bongers MY, Heinz AP. The accuracy of transvaginal ultrasonography in the diagnosis of endometrial abnormalities. *Obstet Gynecol* 1996; **87**: 345–349.

12. Dueholm M, Jensen ML, Laursen H, Kracht P. Can the endometrial thickness as measured by trans-vaginal sonography be used to exclude polyps or hyperplasia in pre-menopausal patients with abnormal uterine bleeding? *Acta Obstet Gynecol Scand* 2001; **80**: 645–651.
13. Goldstein SR. The routine use of ultrasound in the gynecological visit. *Ultrasound Obstet Gynecol* 1996; **8**: 369–370.
14. Omodei U, Ferrazzi E, Ramazzotto F, Becorpi A, Grimaldi E, Scarselli G, Spagnolo D, Spagnolo L, Torri W. Endometrial evaluation with transvaginal ultrasound during hormone therapy: a prospective multicenter study. *Fertil Steril* 2004; **81**: 1632–1637.
15. Goldstein SR, Zeltser I, Horan CK, Snyder JR, Schwartz LB. Ultrasonography-based triage for perimenopausal patients with abnormal uterine bleeding. *Am J Obstet Gynecol* 1997; **177**: 102–108.
16. Caspi B, Appelman Z, Goldchmit R, Ashkenazi M, Haruvy Y, Hagay Z. The bright edge of the endometrial polyp. *Ultrasound Obstet Gynecol* 2000; **15**: 327–330.
17. Naftalin J, Jurkovic D. The endometrial–myometrial junction: a fresh look at a busy crossing. *Ultrasound Obstet Gynecol* 2009; **34**: 1–11.
18. Timmerman D, Valentin L, Bourne TH, Collins WP, Verrelst H, Vergote I; International Ovarian Tumor Analysis (IOTA) Group. Terms, definitions and measurements to describe the sonographic features of adnexal tumors: a consensus opinion from the International Ovarian Tumor Analysis (IOTA) Group. *Ultrasound Obstet Gynecol* 2000; **16**: 500–505.
19. Timmerman D, Verguts J, Konstantinovic ML, Moerman P, Van Schoubroeck D, Deprest J, Van Huffel S. The pedicle artery sign based on sonography with color Doppler imaging can replace second-stage tests in women with abnormal vaginal bleeding. *Ultrasound Obstet Gynecol* 2003; **22**: 166–171.
20. Parsons AK, Lense JJ. Sonohysterography for endometrial abnormalities: preliminary results. *J Clin Ultrasound* 1993; **21**: 87–95.
21. Exalto N, Stappers C, van Raamsdonk LA, Emanuel MH. Gel instillation sonohysterography: first experience with a new technique. *Fertil Steril* 2007; **87**: 152–155.
22. Van den Bosch T, Betsas G, Van Schoubroeck D, Daemen A, Vandenbroucke V, Cornelis A, De Moor B, Deprest J, Timmerman D. Gel infusion sonography in the evaluation of the uterine cavity. *Ultrasound Obstet Gynecol*; 2009; **34**: 711–714.
23. Farquhar C, Ekeroma A, Furness S, Arroll B. A systematic review of transvaginal ultrasonography, sonohysterography and hysteroscopy for the investigation of abnormal uterine bleeding in premenopausal women. *Acta Obstet Gynecol Scand* 2003; **82**: 493–504.
24. Leone FP, Lanzani C, Ferrazzi E. Use of strict sonohysterographic methods for preoperative assessment of submucous myomas. *Fertil Steril* 2003; **79**: 998–1002.
25. Leone FP, Bignardi T, Marcianti C, Ferrazzi E. Sonohysterography in the preoperative grading of submucous myomas: considerations on three-dimensional methodology. *Ultrasound Obstet Gynecol* 2007; **29**: 717–718.
26. Van Holsbeke C, Van Calster B, Testa AC, Domali E, Lu C, Van Huffel S, Valentin L, Timmerman D. Prospective internal validation of mathematical models to predict malignancy in adnexal masses: results from the international ovarian tumor analysis study. *Clin Cancer Res* 2009; **15**: 684–691.
27. Leone FP, Marcianti C, Crepaldi A, Bignardi T, Ferrazzi E. Endometrial hyperplasia at 3D transvaginal sonography by VCI analysis. *Ultrasound Obstet Gynecol* 2007; **30**: 513–514.
28. Alcazar JL, Galvan R. Three-dimensional power Doppler ultrasound scanning for the prediction of endometrial cancer in women with postmenopausal bleeding and thickened endometrium. *Am J Obstet Gynecol* 2009; **200**: 44.e1–44.e6.
29. Opolskiene G, Sladkevicius P, Jokubkiene L, Valentin L. Three-dimensional ultrasound imaging for discrimination between benign and malignant endometrium in women with postmenopausal bleeding and sonographic endometrial thickness of at least 4.5 mm. *Ultrasound Obstet Gynecol* 2009. DOI: 1002/uoq.7445.
30. Leyendecker G, Kunz G, Herberitz M, Beil D, Huppert P, Mall G, Kissler S, Noe M, Wildt L. Uterine peristaltic activity and the development of endometriosis. *Ann N Y Acad Sci* 2004; **1034**: 338–355.

SUPPORTING INFORMATION ON THE INTERNET

The following supporting information may be found in the online version of this article:

Appendix S1 IETA data sheet.